

Hyperspectral (HSI) Oximetry Imaging for Burn Monitoring and early prediction of Burn severity

Case samples for explanation of clinical use (HLI)

Dr. Axel Kulcke / Amadeus Holmer
Diaspective Vision GmbH, Strandstraße 15
18233 Am Salzhaff, OT Pepelow, Germany
office@diaspective-vision.com

©Copyright by Diaspective Vision GmbH, Am Salzhaff 04/2018
No copy or distribution without written permission of Diaspective Vision GmbH

Abstract:

Hyperspectral imaging (HSI) is a noncontact and noninvasive optical modality emerging the field of medical research and clinical practice. The goal of this white paper is to explain possibilities of this modality discussing results of a few case studies to determine the ability of HSI to discriminate burn wounds for degree of tissue damage. The hyperspectral image cubes were processed for microcirculatory parameters for false colour display of the parameters StO₂, NIR Perfusion Index, THI, and TWI.

The suggested image-processing scheme to microcirculatory perfusion parameters allowed mapping dynamic changes of spectral properties within the burn wounds over time. The results of the demonstrated clinical case studies give good support to findings of clinical research on Multispectral and Hyperspectral systems and gives first indication that calculated perfusion parameter images can help to discriminate burn injuries of varying severity. Using this more detailed physiological information, this modality may have relevance for further work to get a better understanding of burn severity and healing and to add more information than Laser Doppler imaging. More clinical experience and controlled studies about the comparison of both optical modalities and the possible advantage of early supportive information in the early burn status and for guidance of debridement procedure should be performed.

1 INTRODUCTION

1.1 Clinical task

In the treatment of larger burn wounds, the determination of the degree of damage (classified as superficial partial thickness or superficial dermal, deep partial thickness, or deep dermal full thickness) is crucial for the selection of the subsequent form of treatment.

Burn depth assessment: In general (in German-speaking countries) a distinction is made into class 1 to class 4. This classification is described in Table 1: Clinical features of burns. Most important for clinical assessment are classes 2a, 2b, and 3:

2a affects the epidermis and the underlying dermis only superficially, 2b goes deeper into the dermis, 3 even deeper into the subcutaneous tissue.

2b, however, can still be differentiated in the superficial 2b, whereby the blood circulation in deeper layers still works and there is still sufficient reason for growth, and deeper 2b, where the blood circulation is already greatly disturbed (deep dermal). At grade 3, the upper skin tissue is necrotic and no longer perfused. Deep 2b and 3 must be treated as early as possible.

Table 1: Clinical features of burns

	1° burn	2a° burn	2b° burn	3° burn	4° burn
Damage	Epidermal layer	Top corium layer, basal cells preserved	Deeper corium layer	Necrosis of the whole dermis	Necrosis of deeper structures: bones, fibers, muscles
Skin colour	Redness, swelling, hyperemia	Redness (blanchable), wet wound bed, normal skin texture	Barely blanchable redness, whitish corium, increased consistency, moist wound bed	Pale, spotted brownish to grey, shiny, increased, rough, tough consistency, dry wound bed	Black, charred
Blistering	None	Blistering	Blistering	Dry blistering	None
Pinprick test	Bleeds with any pinprick	Bleeds with any pinprick	Bleeds visibly only after deep intracutaneous pricking	Not bleeding	Not bleeding
Pain	Aching when touched	Aching when touched	Strongly decreased sense of pain	Sense of pain is lacking	Sense of pain is lacking
Healing	Healing without scarring (<1 week appr.)	Healing without scarring (1-2 weeks appr.)	Healing with scarring (> 3 weeks appr.)	Spontaneous healing not possible	Emergence of blunts

Regarding the necessary treatment, 2a and lower grade 2b (often scald injuries) can be conservatively self-healing wounds, and deep 2b is a surgical grade injury.

LDI (Laser-Doppler-Imaging) devices are not using this degree classification but instead make suggestions with respect to a probability of healing in different periods of time.

Superficial wounds have the capability of self-healing without scarring and are suitable for conservative therapy; deeper wounds have to be treated surgically to ensure a good functional and cosmetical outcome. Generally, an early secure determination of the degree of damage is important for an adequate and efficient treatment [1–3].

Up to now, assessment of the burn degree is usually performed by visual inspection. That means: characteristic optical, especially colour features are examined by a human clinical expert (the so-called *diagnostic view*). The assessment based on these impressions is not objective, depends on the subjective experience of the examiner, and is error prone (25-40% concerning the discrimination of superficial and deep dermal wounds) [4,5].

In daily practice, before the patient is transferred to a burn center, a physician or nurse with relatively little experience in burn wounds initially assesses burn size and depth with only 60% and 51% accuracy, respectively. Clinical judgment alone is the standard of care in burn depth assessment by experts with a reported accuracy between 70–80%. At this point, it should be noted that the human eye can only detect the visual spectral range and thus can capture only

superficial tissue information due to its high absorption.

Imaging technologies show greater accuracy in burn depth assessment (>80%) compared to clinical judgment alone. [6]

The development of an objective measurement method for the early reliable determination of the burn depth is a difficult problem due to the variability and complexity of the system "burned skin".

Various physical methods have been tested over years [7–9]. In recent years, most frequently in the clinical environment, laser Doppler imaging (LDI) or laser speckle imaging (LSI) were used. However, both of them are rarely in routine use.

Both methods provide comparable results, with the LSI being the newer, easier-to-use method. [7]. LDI is the most commonly used method in clinical practice [8], but has not achieved the status of a standard diagnostic tool for burns.

Therefore, there is still a need for a diagnosis-supporting method which provides high reliability of burn degree determination and which is useable in clinical practice and also by relatively inexperienced clinicians.

1.2 Multispectral (MSI) - and Hyperspectral Imaging (HSI) for the Assessment of Burns

MSI and HSI are techniques which combine imaging with spectroscopic methods. An overview of medical applications for this technology is given in [10–12].

Parallel to the development of clinical LDI devices for Burn Assessment, several studies on the use of MSI and HSI devices for burn depth assessment were conducted. Due to the lack of suitable clinical systems,

the technology attracted attention in biomedical research but the clinical data were limited.

MSI, which actually has its origins in burn care, may ultimately meet a high number of requirements for burn assessment in routine clinical use. [6]

The first attempts to use MSI technology for burn assessment in biomedical research were made early [13]. First results with an MSI device in a clinical setting were that it improved the ability to distinguish between partial thickness burns of varying severity and thereby to better assess, whether a patient required surgery or not [14].

Plenty of work on burn assessment was done by the group of Sowa et al. with a multi-spectral NIR Imaging device. Some citations of their work are given next:

Burn injuries were identified based on the relative change and distribution in oxygen content and blood volume 4 hr post injury. Oxygen saturation images provide spatially related hemodynamic changes occurring with thermal damage.

These images are an effective means of localizing the burn and assessing the total surface area of the damaged tissue. Oxygen saturation images can be used to identify near-surface to subsurface physiological changes. Depth-dependent spectroscopy has been shown to determine oxygen saturation and blood volume changes deep within thermally injured tissue. Burn injuries were identified based on the relative change and distribution in oxygen content and blood volume at various depths in the tissue.

NIR spectroscopy may provide clinical personnel with a useful tool in the assessment and evaluation of burns. [15–18]

The results of a more recent publication of this group regarding the classification of burn wounds from multispectral data are cited next:

While that is not the case in the current model, oxygen saturation may have implications for burn healing at later time points. Regardless, SFDI appears to be able to noninvasively track certain important aspects of burn depth. The model displayed reasonable ranking quality as summarized by the area under the receiver operator characteristics curve, AUC =0.879. Fixing the threshold for the class boundaries at 0.5 probability, the model sensitivity (true positive fraction) to separate deep from shallow burns was 0.90, while model specificity (true negative fraction) was 0.83. Using an acute porcine model of thermal burn injuries, the potential of near-infrared spectroscopy to distinguish between shallow healing burns and deeper burn injuries was demonstrated. While these results should be considered as preliminary and require clinical validation, a probabilistic model capable of differentiating these classes of burns would be a significant aid to the burn specialist [18].

A different group using MSI technology got comparable results:

“Histology confirmed that we achieved various partial thickness burns. Analysis of spectral images show that MSI detects significant variations in the spectral profiles of healthy tissue, superficial partial thickness burns, and deep partial thickness burns. The absorbance spectra of 515, 542, 629, and 669 nm were the most accurate in distinguishing superficial from deep partial thickness burns, while the absorbance spectra of 972nm was the most accurate in guiding the debridement process. Conclusion: The ability to distinguish between partial thickness burns of varying severity to assess whether a patient requires surgery could be improved with an MSI device in a clinical setting [19]

Important with the preceding context is the conclusion that the wavelength of 972nm was the most accurate in guiding the debridement process. This wavelength is located exactly at the water absorption band and so relates to the TWI parameter of the TIVITA tissue HSI system.

Since hyperspectral systems are more sophisticated from the technical side, more studies were published most recently.

Hyperspectral Study I:

One study was published by the group of Randeberg et al.:

The study was performed in control environment and over limited post-injury time (8 h); however, we believe that spectral-spatial classification can be used for initial identification of burn wound of different severity....

The results of this study indicate that unsupervised spectral-spatial segmentation applied on hyperspectral images can discriminate burn injuries of varying severity. [20]

Hyperspectral Study II:

A second study was published by the group of Lalikos et al.

Results: Three levels of burn depth were verified histologically: intermediate- dermal (ID), DD, and full-thickness. At 24 hours post injury, total hemoglobin (tHb) increased by 67% and 16% in ID and DD burns, respectively. In contrast, tHb decreased to 36% of its original levels in full thickness burns. Differences in deoxygenated and tHb among all groups were significant ($P < 0.001$) at 24 hours post injury.

Conclusions: HSI was able to differentiate among 3 discrete levels of burn injury. This is likely because of its correlation with skin perfusion: superficial burn injury causes an inflammatory response and increased perfusion to the burn site, whereas deeper burns destroy the dermal microvasculature and a decrease in perfusion follows. This study supports further investigation of HSI in early burn depth assessment. [21].

Lalikos' group relates the burn depth and changes of extracted medical parameters to physiological reasons, which is in our opinion the correct interpretation of the results.

They created an important graphic (Figure 1) which demonstrates the typical development of oxygenation with different burn depth over time.

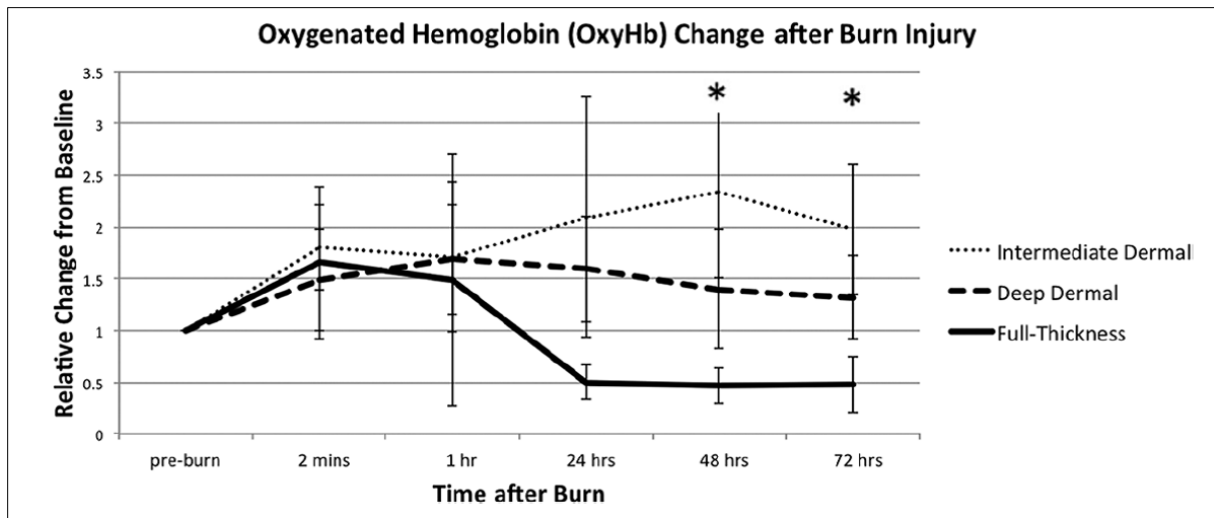


Figure 1 Oxygenated hemoglobin (OxyHb) variations in 3 depths of burn. OxyHb is relative to its preburn baseline for the 3 depths of burn, measured during the first 72 hours post injury. All values are expressed as mean \pm SD of the mean. Statistical significance of P value of less than 0.05 between ID and DD burns is indicated with an asterisk(*) [21].

Later on, comparable time developments will also be displayed in the case studies of the TIVITA system.

Hyperspectral Study III:

Chin et. Al. presented work using a Liquid Crystal Tunable Filter (LCTF) based HSI device in the spectral range from 420 nm - 750 nm:

The burn areas of patients were marked with different colours which represent a different burn degree and the spectral imaging system has thus been proven to have the ability to classify the burn areas through comparing their reflective spectral curves with characteristic spectrum of the different burn degree in spectral database in the future [22].

A technology closely related to MSI technology was also used for burn assessment:

Tissue oxygen saturation (s_{tO_2}) and total hemoglobin (ctHbT) differentiated superficial partial thickness burns from more severe burn types after 2 and 72 h, respectively ($p < 0.01$), but were unable to differentiate deep partial from full thickness wounds in the first 72 h. Tissue scattering parameters separated superficial burns from all burn types immediately after injury ($p < 0.01$), and separated all three burn types from each other after 24 h ($p < 0.01$).[23]

For completeness other MSI and HSI studies should also be referenced here [24–26].

1.3 Laser Doppler Imaging (LDI) and Laser Speckle Imaging (LSCI)

LDI and LSCI are non-invasive and fast techniques for measuring microvascular blood flow and both have recently found clinical use for burn assessment and evaluation of flaps.

LDI determines a local measurement parameter that correlates with the important functional system parameter "perfusion" as a vitality index. Since this measurement parameter is not correlated with a precisely definable system parameter, it is not absolutely evaluable. Most other tested physical methods also specialize in measuring a wound's composition or feature, but this is not enough to ensure a reliable determination of wound status (at least the degree of damage graded in the burn degree as defined above) [27]. Therefore, there is still a need for a diagnosis supporting method that provides high reliability of burn degree determination and which can easily be used in clinical practice and even by relatively inexperienced clinicians.

The requirement for a measuring method is thus to include sufficient information about the individual and local condition of the burn wound in order to achieve a reliable determination of the degree of burn depth. In particular, the primary diagnosis (as early as possible, ideally immediately after the first cleansing or debridement of the burn wound) should allow the distinction between grades 2a and 2b, to provide practically the best possible estimate of the remaining self-healing potential (2a).

Several work and clinical studies were conducted, to correlate the arbitrary units of LDI flow parameter of the MOOR LDI system to healing time [28–32].

Pape et al. [33] reported an audit of wound healing at 21 days for 76 intermediate depth wounds in 48 patients. Results showed the moorLDI2-BI to be 97% accurate (74/76) in predicting wound healing at 21 days compared with 70% (53/76) for clinical evaluation (no statistical comparison reported). Hoeksema et al. [34] investigated the changing accuracies of laser Doppler imaging and clinical evaluation over days 0, 1, 3, 5, and 8 after injury. Forty patients with intermediate depth burn wounds were scanned using the moorLDI2-BI. The final assessment of wound depth showed a deep partial or full thickness burn in 14 patients, 12 of whom had a skin graft, and a superficial dermal burn in 26 patients. Accuracies on days 0, 1, 3, 5, and 8 were 41%, 62%, 53%, 71%, and 100% respectively by clinical evaluation, and 55%, 80%, 95%, 97%, and 100% respectively by laser Doppler imaging. The burn wound depth accuracy using the moorLDI2-BI was significantly higher than clinical evaluation on day 3 ($p < 0.001$) and day 5 ($p = 0.005$) but not on days 0, 1, or 8.

Clinical utility outcomes associated with the technology are avoiding unnecessary operations, extent of surgery, number of dressing changes, complications, and length of stay in hospital. Longer-term outcomes are extent and type of scarring and the recovery of pre-injury function.

Laser Doppler Imaging has got different points to consider. E.g. a typical image capture takes 30-40 seconds. If movements of the object happen during this time, the recorded values change. As a result of

patient motion during image acquisition, measured perfusion values are higher [9].

In LSCI, tissue motion increases and measurement angles beyond 45° decrease the measured perfusion. These findings have to be considered when LSCI is used to assess moving or curved tissue surfaces, which is common in clinical applications [27].

On the other hand, there is also a critical review on burn depth assessment using LSCI [35,36]. But there are also studies which emphasize the economic value of LDI devices for burn assessment and thereby the importance of optical methods for clinical burn treatment.

“Laser Doppler imaging improved therapeutic decisions.....and has the potential to save € 875 per patient” [37]

1.4 Comparison of HSI and LDI technology

HSI and LDI are two optical imaging methods for the assessment of microcirculation in human tissue. So from the general scientifically point of view, both technologies qualify for burn assessment which was explained by Randeberg et al:

HSI was able to differentiate among 3 discrete levels of burn injury. This is likely because of its correlation with skin perfusion: superficial burn injury causes an inflammatory response and increased perfusion to the burn site, whereas deeper burns destroy the dermal microvasculature and a decrease in perfusion follows. [21]

In order to show the correlation of the two methods from the scientific point of view, Figure 2 was added:

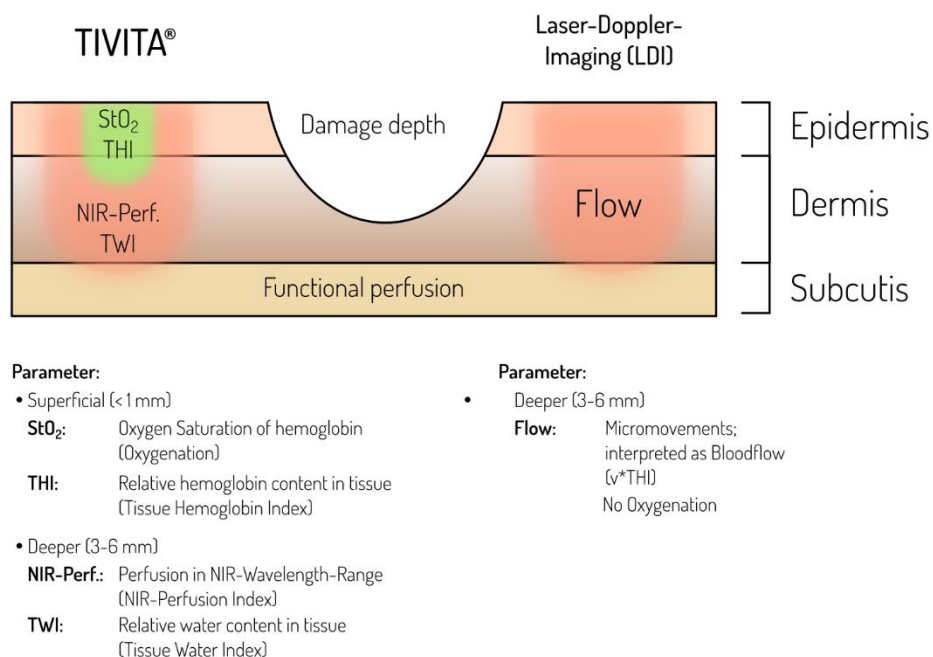


Figure 2: Measuring parameters of HSI and LDI technology for burn assessment

Table 2 Fehler! Verweisquelle konnte nicht gefunden werden.shows a comparison of the two available clinical systems for HSI and LDI technology:

Table 2: Comparison of two clinical HSI and LDI systems

	HSI (TIVITA)	LDI (moorLDI2-IR)
Technology	Hyperspectral Imaging	Laser Doppler Imaging
Approval	CE marked	CE marked, FDA 510k
CE Class	I	Ila
Laser	No laser	Laser Class 3R
Operator and patient protection	None	Protective Eyewear
Patient insulation	Class I	Class I
Distance to patient	50 cm	20 cm or 100 cm
Image resolution	640 x 480	Max. 256 x 256;
Scan time	7 sec	40 sec (@ 12.5 x 12.5 cm / 64 x 64 px) 6 min (@ 50 x 50 cm / 256 x 256 px)
Area	30 cm x 22 cm	25 cm x 25 cm / 50 cm x 50 cm
Color image	Yes, normed, extracted from HSI data cube	Yes
Parameter images	StO ₂ (%), THI (AU), NIR Perfusion (AU), TWI (AU)	Flux (AU)
Documentation software	Yes	Yes
Patient report	Yes	Yes
DICOM	No	Yes

A comparison of the Laser Speckle Technology in comparison with a modified MSI technology was performed in a scientific and clinical collaboration of the Beckman Institute in Irvine/CA:

We have investigated two non-invasive tools: SFDI, capable of characterizing in-vivo scattering and absorption changes, and LSI, capable of characterizing blood flow changes, as methods to non-invasively predict burn severity. Burns ranging from superficial partial thickness to full thickness in a porcine model were monitored over three days. Here, we have demonstrated that monitoring changes in blood flow can distinguish superficial partial and deep partial thickness burns at one hour after burn injury. Additionally changes in the reduced scattering coefficient can differentiate superficial partial, deep partial and full thickness burns at one hour after injury. These techniques have the potential to predict burn severity at the earliest stages, which is critical for guiding treatment options [38,39].

2 2 METHODS

2.1 Image Acquisition

HSI Data Cubes of the burn wounds were made as early as possible (if possible within the first 24 to 48 hours after the injury had happened), at the latest before the first debridement got started. After the first debridement, documentation was taken on the clean dry wound and periodically during the healing process. The imaging process takes appr. 30 seconds (thereof 7 sec image acquisition) and the recording is

carried out at a distance of 50 cm from the wound and practically does not affect the usual treatment process. The colour and evaluated physiological parameter images are displayed directly on the screen and the datasets are automatically stored in the documentation area of the software as soon as they have been recorded. Thus, the data sets are also available in the database for subsequent quantitative analysis and evaluation during the healing process.

By additional use of the marker tool, certain areas of the burn wound can be analysed quantitatively.

By means of different case studies, clinical aspects of the assessment of burn wounds will be presented with the help of hyperspectral analysis of physiological parameters. The case studies were acquired from three clinics (Städt. Klin. Dessau, University Hospital Greifswald, and Unfallkrankenhaus Berlin). The data were collected during the routine treatment as the images for the objective documentation of the course of treatment were clinically indicated, and with written consent of the patients.

Out of the standard documentation of about 30 treatments, five examples with different aspects are discussed here.

3 RESULTS

3.1 Case study 1 with scald on breast of child

The first example is a whole clinical documentation of the treatment and healing process from hospital admission till the 11th day after injury (Figure 3).

The visual inspection of the surgeon resulted in a scald with grade 2-a-b burn

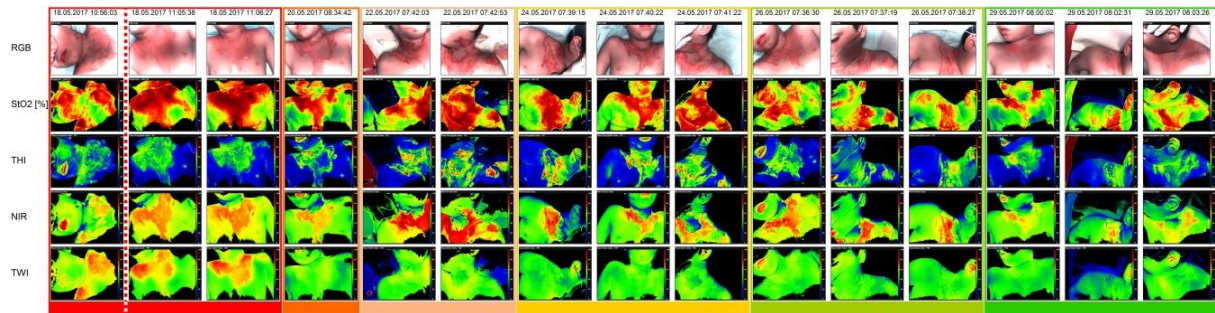


Figure 3: Representation of a typical documentation series of the treatment and healing process. The red dashed line marks the images before and after surgical debridement. The explanations of the findings are given in the text

The vertical dashed red line marks the time point where the initial debridement process was done. The underlying colour code shows the time line of the images taken during the healing process. These images were taken appr. every second day. The information from the parameter images, calculated from the HSI Data cube, are explained next.

NIR Perfusion: In the case of NIR perfusion, one recognizes locally different elevations in the values inside the wound area. It can be assumed that stronger increases are associated with an elevated layer thickness of the damaged tissue and thus provide a measure for the local variation of the depth of burn. Over time, until the 4th day after the injury, an increase in NIR perfusion is seen which can correlate with an increase of the inflammatory reaction of the tissue. In the further course, a successive reduction of the perfusions happens towards the basic values of the surrounding non-damaged tissue.

StO₂: A similar course is also shown by the superficial oxygenation StO₂.

THI: The THI shows increased values inside the burn wound because the skin is damaged and therefore increased hemoglobin becomes visible to the camera. The values are increasing during the first six days and in addition are getting more distributed and structured inside the wound. This is on one hand related to the increased perfusion, on the other hand

to the differentiation of the wound. Higher THI values normally correlate with thinner epidermis layer. In the course of time, values are decreasing slowly towards the normal values of the surrounding skin. This is due to the healing process and indicates on the formation of a lower perfused new cover layer of the skin (new epithelisation tissue).

TWI: Water content: On the first day after the injury, the water content is significantly increased inside the burn wound. On the second day, it has normalised and subsequently remains stable.

These courses can also be evaluated quantitatively by the marker tool of the TMITA suite which is shown in Figure 4.

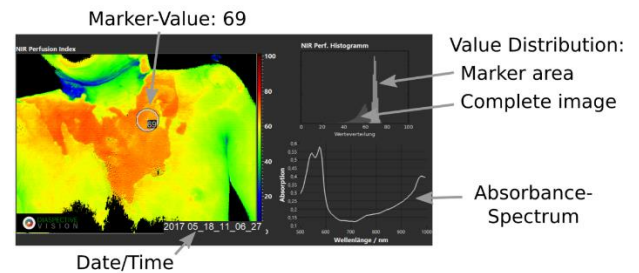


Figure 4: Example for quantification of parameter values inside the parameter image

In Figure 5 the changes of parameter values before and after debridement are given:

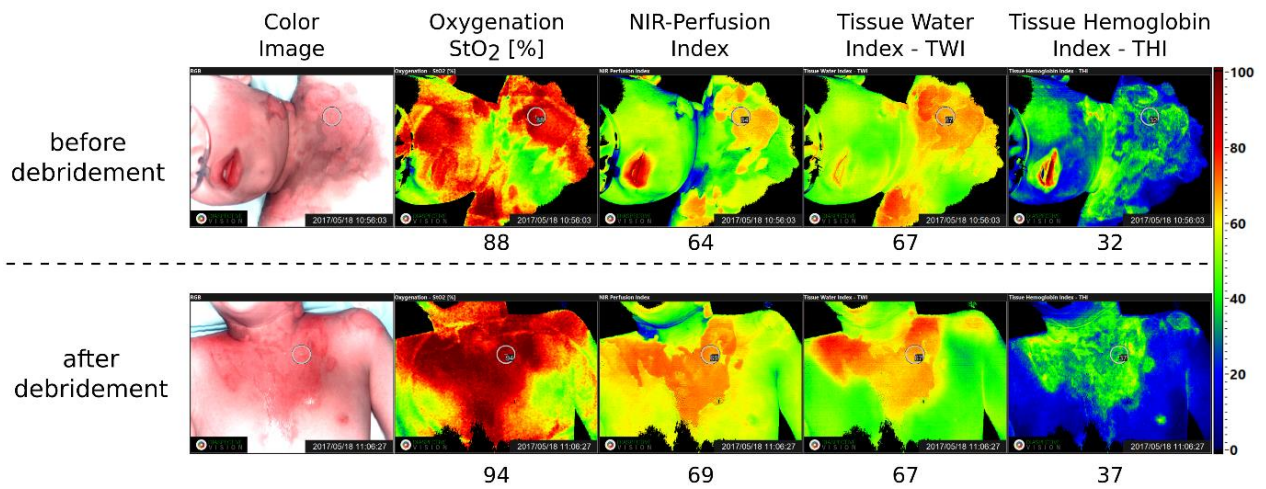


Figure 5: Quantification of parameters at one single position inside the burn before and after debridement

A different display of the documentation with a reduced number of images for better visualization is given in Figure 6.

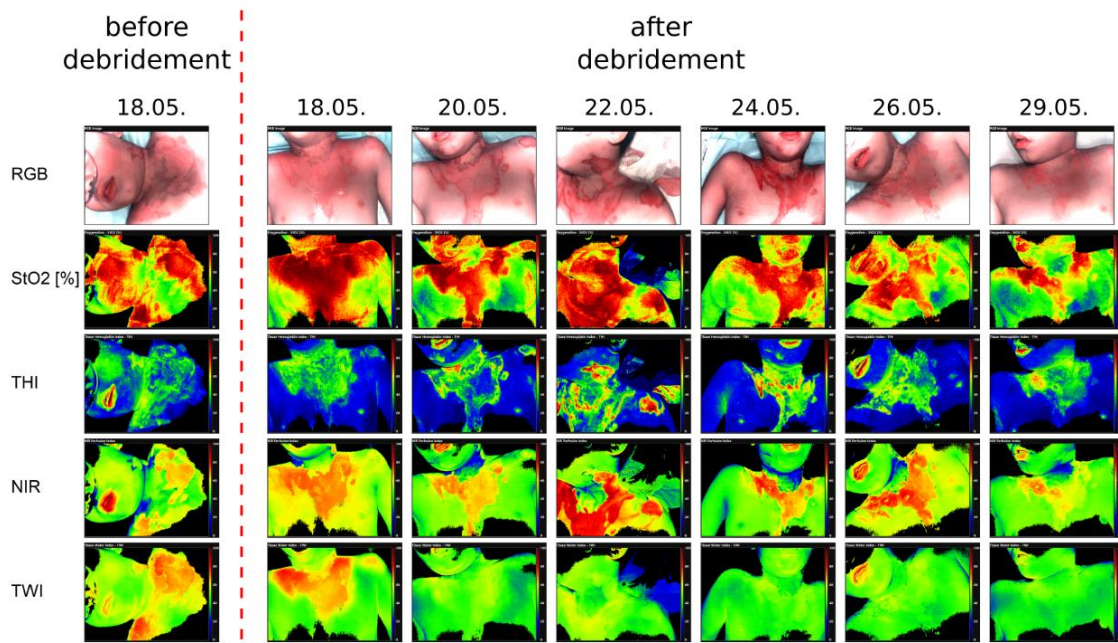


Figure 6: Time development of the reduced documentation (only one image for each day that was measured)

The development of the parameters in the time sequence is shown in Figure 7.

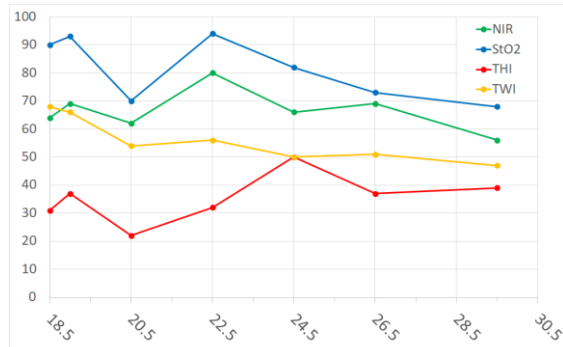


Figure 7: Time development of the medical parameters at one position inside the burn

3.2 Case study with flap transplantation

The example shown in Figure 8 documents a case where the surgeon decided at an early stage to transplant tissue on the burn wound.

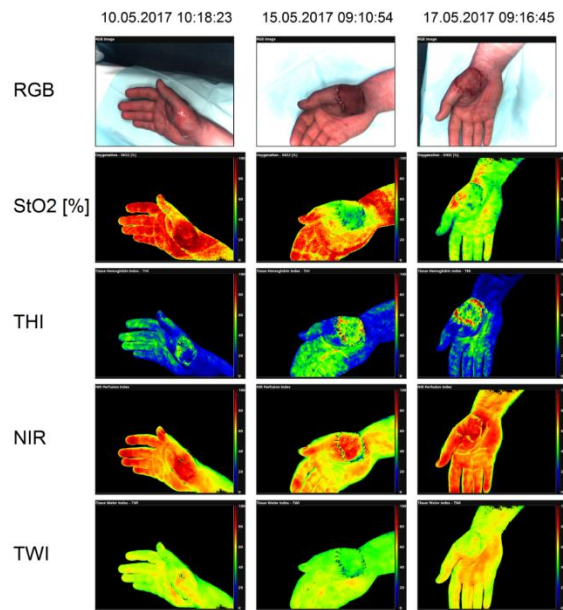


Figure 8: Flap transplantation on a 2a-b burn wound of a hand with fast healing process

In tissue transplantation, the following can clearly be stated: in contrast to transplantation on a normal chronic wound, transplantation on a burn wound is done onto a highly perfused tissue (inflammatory). Thus, very high NIR perfusion values can be seen for low StO₂ values on the upper layer of the transplant. Two days after the transplant, it is obvious that the values of StO₂ and NIR perfusion have adapted to the healthy surrounding tissue as much as possible. The values are still elevated by default, so the healing process is still ongoing. However, this transplantation shows that the growth of the transplanted tissue is very much accelerated by the very high underlying

perfusion in comparison to transplantations on, e.g., low-perfused wound tissue of venous leg ulcers.

3.3 Case study of foot

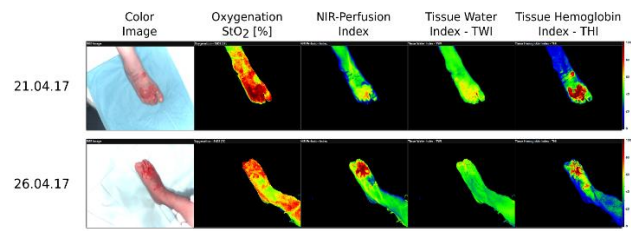


Figure 9 Typical burn development on a foot

There could be a possible additional patient and system benefit obtained by using the HSI system to define accurately the margins of surgical areas for the skin graft operations, thus helping to limit the extent of excision and grafting in some patients (Figure 9).

3.4 Case study I of hand

Another interesting case study is the hand shown in Figure 10. This burn shows many significantly different areas within the burn wound: The water content is significantly increased in certain areas and the blister filled with liquid can easily be seen. The high THI in one area suggests that the uppermost skin layer is already missing.

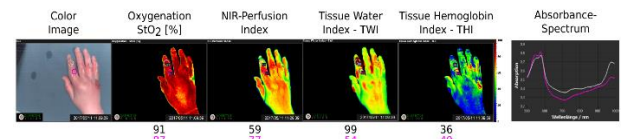


Figure 10: Burn wound on hand with locally strong structured perfusion states.

3.5 Case study II, III and IV of hand

In the next 3 cases different examples of burn wounds are shown. In Figure 11, perfusion of the entire hand is increased compared to normal perfused tissue (StO₂ ~80% vs. 60-70%; NIR ~80-90 vs. 50-70), especially in the open blisters. Also the amount of water is slightly increased in comparison with normal values.

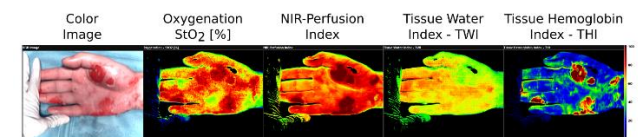

Figure 11: Strongly segmented burn wound of hand

These observations can also be made for Figure 12, except that the water index is within a normal range. The RGB image shows that there is a greyish discoloration of the skin around the burn. The NIR perfusion Index and the oxygenation are not increased in these areas.

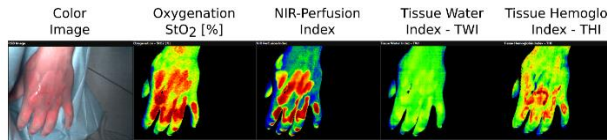


Figure 12: Burn wound of hand

Figure 13 shows recordings of a kids palm before and after debridement on the right hand and after debridement on the left hand. The debridement process increases the NIR Perfusion Index significantly and also the oxygenation is increased although it is initially very high.

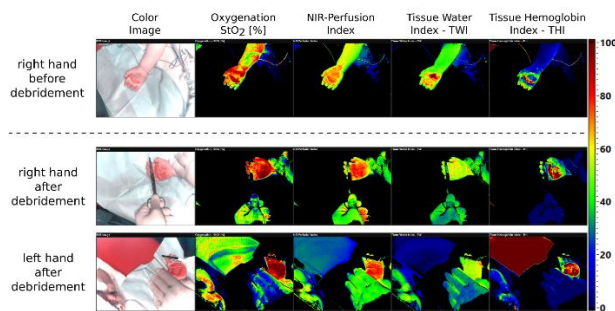


Figure 13: Illustration of a burned palm before (right hand) and after debridement (left and right hand)

The high water index in the first recording shows that in this case the epidermis has already separated from the underlying tissue and a water layer has evolved. This tissue is removed during the debridement process.

The high THI in one zone points to the fact that the epidermis is not existing any more and that after debridement, the palm of the hand is heavily supplied with blood. So the open tissue should be covered by a protective layer against environmental influences.

3.6 Case study V of hand

One case of a burn wound was documented during routine wound treatment (Figure 14). Specific data of the surgeon's assessment are missing. Due to the long treatment process culminating in a tissue transplantation, the case was chosen to be displayed here.

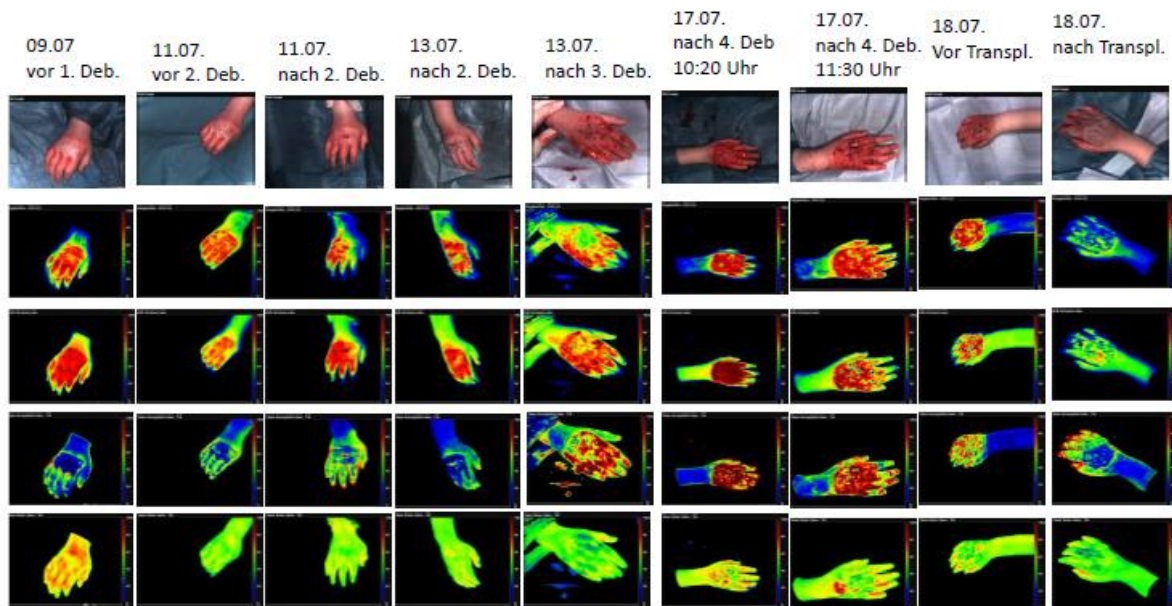


Figure 14: Wound documentation of burn wound of a hand.

4 DISCUSSION

4.1 Objective documentation of the treatment and healing process.

In the treatment of children with burned skin, burns in result of scalding have increased sharply in recent years. It is well known that a non-ideal course of

healing leads to severe scarring, with which patients are generally confronted during the entire rest of their lives. Scarring causes many years of orthopedical and psychological problems, which often mean that patients are unable to enter a normal work process throughout their lives [Krause-Wloch, Salzhemmendorf].

In order to optimize the treatment of children in the medium term, an objectified documentation of the healing process must be introduced in the first step. This is still not guaranteed in everyday clinical practice. Although the data of the LDI technique are suitable for the diagnosis and documentation of the first approx. 5 days after the burn, in the further healing process the informative value of the data becomes smaller.

So the TIVITA Tissue including the wound documentation tool is the perfect system for setting up a routine documentation of the treatment process. Due to the normalized colour images extracted out of the HSI data cubes and the additional physiological parameter images, a comprehensive documentation, an objective evaluation, a controlled improvement of the treatment process and education of surgeons and clinical staff based on the documentation is possible.

4.2 NIR Perfusion Index

The NIR parameter is most comparable to the flow parameter of LDI systems. In the first stage of the burn wound the parameter is very high and is decreased over time. Whether the increase after a first decrease, which could be shown in Section 3.1, can be measured reproducibly, must be demonstrated by further investigations.

4.3 Tissue Water Index

The Tissue Water Index parameter is an important information source and literature shows that it is suitable for controlling the debridement process [19]. The typical course over time is a first increase followed by a decrease over the healing time. These statements must be scientifically proven in further investigations, but it can be assumed that the TIVITA system at this point has a clear advantage over LDI.

4.4 Tissue Hemoglobin Index

With the parameter THI, open tissue can be recognized and during the healing it can be inferred from the reduction of its value how the skin covering progresses.

5 CONCLUSIONS

This case report is a documentation of the first very preliminary applications of the TIVITA tissue in burn assessment and treatment and for healing documentation.

- The case studies show high information content inside the parameter images, differentiated in different parameters.
- From the scientific point of view, the HSI NIR Perfusion Index data are mostly correlated to the LDI Flow data. Since both systems use NIR optical radiation in the equivalent spectral range for obtaining information, they have a comparable penetra-

tion range and thus detection range into the tissue. Since the LDI systems parameter "Flow" is generated by the micro-motion in the tissue, which itself is caused by the blood flow through the tissue, the spectrally measured HSI parameter "NIR perfusion index" provides comparable information.

- The parameter images StO₂, THI and TWI provide additional information on the burn structure and healing process. Especially the TWI provides very important information about the burn wound in the first hours and up to a few days. This has already been mentioned in [19], where this wavelength (970 nm) was identified as the most accurate for guiding the debridement process
- The motion-dependent artifacts of LDI technology can not occur in hyperspectral technology which is based on the technical recording principle.
- The comparison of the preliminary case studies with published results for MSI and HSI suggests a good correspondence.
- There could be a possible additional patient and system benefit obtained by using the HSI system to define accurately the margins of surgical areas for the skin graft operations, so helping to limit the extent of excision and grafting in some patients.

With the presented observations it can be assumed, that HSI can measure more parameters of the burn and therefore allows better and more complete burn assessment, leading to better treatment, objectified surgical interventions and verification of performed operations.

The next step for the use of HSI or MSI devices in routine practice is to perform controlled studies for the correlation of HSI and LDI parameters and the usefulness of the parameter TWI for guidance in debridement.

Burn injuries were identified based on the relative change and distribution in oxygen content and blood volume at various depths in the tissue. NIR spectroscopy may provide clinical staff with a useful tool for the assessment and evaluation of burns.

First qualitative statements about the perfusion parameters (by Dr. Dr. J. Marotz):

The acute reaction in 2a and superficial 2b burns (2b1) shows a very high StO₂ and THI value, NIR is in a high to very high range, and in some cases an increased water accumulation (edema) is recognizable.

In lower-grade 2b burns (2b2), the initial StO₂, THI, and NIR values are still mediocre, but lower than the acute values 2a and 2b1.

For third-degree burns, low parameter values are already present in this phase (no water).

At 2b1 and 2b2 the values may change within the first hours ((stasis formation (StO₂ and THI) and NIR

development)). These changes are important for the exact evaluation.

In the second phase from the third day, 2a-burns show increased StO_2 and THI values compared to normal values (environment) and increased NIR values. At grade 2b1 the StO_2 and THI are decreased, but NIR is still good and shows the ability to heal. At grade 2b2, NIR is already lowered, so that the ability to heal has become worse. At level 3, the typical necrosis signs can be seen in the spectra.

Roughly, one can say that NIR primarily reflects the ability to heal; this also correlates with the LDI flow, which is determined at a similar depth.

REFERENCES

- [1] Janzekovic Z. A new concept in the early excision and immediate grafting of burns. *The Journal of trauma* 1970; 10: 1103–1108.
- [2] Orgill DP. Excision and skin grafting of thermal burns. *The New England journal of medicine* 2009; 360: 893–901.
- [3] Thomsen M, Alsbjorn BF. Development of the treatment of partial skin thickness burns since the Second World War: an overview. *Burns : journal of the International Society for Burn Injuries* 1992; 18 Suppl 2: S11-3.
- [4] Afromowitz MA, van Liew GS, Heimbach DM. Clinical evaluation of burn injuries using an optical reflectance technique. *IEEE transactions on biomedical engineering* 1987; 34: 114–127.
- [5] Micheels J, Alsbjörn B, Sørensen B. Clinical use of laser Doppler flowmetry in a burns unit. *Scandinavian journal of plastic and reconstructive surgery* 1984; 18: 65–73.
- [6] Thatcher JE, Squiers JJ, Kanick SC, et al. Imaging Techniques for Clinical Burn Assessment with a Focus on Multispectral Imaging. *Advances in wound care* 2016; 5: 360–378.
- [7] Machens HG, Mailänder P, Kremer M, Reimer R, Berger A. Techniken zur postoperativen Überwachung der Gewebedurchblutung nach freier mikrovaskulärer Gewebetransplantation. *Handchirurgie, Mikrochirurgie, plastische Chirurgie : Organ der Deutschsprachigen Arbeitsgemeinschaft für Handchirurgie : Organ der Deutschsprachigen Arbeitsgemeinschaft für Mikrochirurgie der Peripheren Nerven und Gefäße : Organ der V...* 1999; 31: 107–112.
- [8] Kaiser M, Yafi A, Cinat M, Choi B, Durkin AJ. Noninvasive assessment of burn wound severity using optical technology: a review of current and future modalities. *Burns : journal of the International Society for Burn Injuries* 2011; 37: 377–386.
- [9] Devgan L, Bhat S, Aylward S, Spence RJ. Modalities for the assessment of burn wound depth. *Journal of burns and wounds* 2006; 5: e2.
- [10] Lu G, Fei B. Medical hyperspectral imaging: a review. *Journal of biomedical optics* 2014; 19: 10901.
- [11] Allen J, Howell K. Microvascular imaging: techniques and opportunities for clinical physiological measurements. *Physiological measurement* 2014; 35: R91-R141.
- [12] Li Q, He X, Wang Y, Liu H, Xu D, Guo F. Review of spectral imaging technology in biomedical engineering: achievements and challenges. *Journal of biomedical optics* 2013; 18: 100901.
- [13] Anselmo VJ, Zawacki BE. Multispectral photographic analysis. A new quantitative tool to assist in the early diagnosis of thermal burn depth. *Annals of biomedical engineering* 1977; 5: 179–193.
- [14] Eisenbeiss W, Marotz J, Schrade JP. Reflection-optical multispectral imaging method for objective determination of burn depth. *Burns : journal of the International Society for Burn Injuries* 1999; 25: 697–704.
- [15] Leonardi L, Sowa MG, Payette JR, Mantsch HH. Near-infrared spectroscopy and imaging: a new approach to assess burn injuries. *American clinical laboratory* 2000; 19: 20–22.
- [16] Leonardi L, Sowa MG, Payette JR, et al. Applications of visible near-infrared spectroscopy and imaging in burn injury assessment. In: Mahadevan-Jansen A, Puppels GJ, editors: SPIE; 2000. p. 83 (SPIE Proceedings).
- [17] Sowa MG, Leonardi L, Payette JR, Fish JS, Mantsch HH. Near infrared spectroscopic assessment of hemodynamic changes in the early post-burn period. *Burns : journal of the International Society for Burn Injuries* 2001; 27: 241–249.
- [18] Sowa MG, Leonardi L, Payette JR, Cross KM, Gomez M, Fish JS. Classification of burn injuries using near-infrared spectroscopy. *Journal of biomedical optics* 2006; 11: 54002.
- [19] King DR, Li W, Squiers JJ, et al. Surgical wound debridement sequentially characterized in a porcine burn model with multispectral imaging. *Burns : journal of the International Society for Burn Injuries* 2015; 41: 1478–1487.
- [20] Paluchowski LA, Nordgaard HB, Bjorgan A, Hov H, Berget SM, Randeberg LL. Can spectral-spatial image segmentation be used to discriminate experimental burn wounds? *Journal of biomedical optics* 2016; 21: 101413.
- [21] Chin MS, Babchenko O, Lujan-Hernandez J, Nobel L, Ignatz R, Lalikos JF. Hyperspectral Imaging for Burn Depth Assessment in an Animal Model. *Plastic and reconstructive surgery*. Global open 2015; 3: e591.
- [22] Luo Y, Huang LX, Yang J-j, Shen Z-X, Zhang D-Y, Wu J. Research on application of spectral imaging technology in determining on thermal burn degree. In: LeVan PD, Sood AK, Wijewarnasuriya PS, D'Souza AI, editors: SPIE; 2012. 85120S (SPIE Proceedings).
- [23] Mazhar A, Saggese S, Pollins AC, Cardwell NL, Nanney L, Cuccia DJ. Noncontact imaging of burn depth and extent in a porcine model using spatial frequency domain imaging. *Journal of biomedical optics* 2014; 19: 86019.
- [24] Ye H, De S. Thermal injury of skin and subcutaneous tissues: A review of experimental approaches and numerical models. *Burns : journal of the International Society for Burn Injuries* 2017; 43: 909–932.
- [25] Goertz O, Ring A, Köhlinger A, et al. Orthogonal polarization spectral imaging: a tool for assessing burn depths? *Annals of plastic surgery* 2010; 64: 217–221.
- [26] Calin MA, Parasca SV, Savastru R, Manea D. Characterization of burns using hyperspectral imaging technique - a preliminary study. *Burns : journal of the International Society for Burn Injuries* 2015; 41: 118–124.
- [27] Zötterman J, Mirdell R, Horsten S, Farnebo S, Tesselar E. Methodological concerns with laser speckle contrast imaging in clinical evaluation of microcirculation. *PLoS one* 2017; 12: e0174703.
- [28] Shin JY, Yi HS. Diagnostic accuracy of laser Doppler imaging in burn depth assessment: Systematic review and meta-analysis. *Burns : journal of the International Society for Burn Injuries* 2016; 42: 1369–1376.
- [29] Pape SA, Baker RD, Wilson D, et al. Burn wound healing time assessed by laser Doppler imaging (LDI). Part 1: Derivation of a dedicated colour code for image interpretation. *Burns : journal of the International Society for Burn Injuries* 2012; 38: 187–194.
- [30] Monstrey SM, Hoeksema H, Baker RD, et al. Reprint of: Burn wound healing time assessed by laser Doppler imaging. Part 2: Validation of a dedicated colour code for image interpretation. *Burns : journal of the International Society for Burn Injuries* 2012; 38: 195–202.
- [31] Hoeksema H, Baker RD, Holland AJA, et al. A new, fast LDI for assessment of burns : a multi-centre clinical evaluation. *Burns : journal of the International Society for Burn Injuries* 2014; 40: 1274–1282.

- [32] Baker RD, Weinand C, Jeng JC, et al. Using ordinal logistic regression to evaluate the performance of laser-Doppler predictions of burn-healing time. *BMC medical research methodology* 2009; 9: 11.
- [33] Pape SA, Skouras CA, Byrne PO. An audit of the use of laser Doppler imaging (LDI) in the assessment of burns of intermediate depth. *Burns : journal of the International Society for Burn Injuries* 2001; 27: 233–239.
- [34] Hoeksema H, van de Sijpe K, Tondou T, et al. Accuracy of early burn depth assessment by laser Doppler imaging on different days post burn. *Burns : journal of the International Society for Burn Injuries* 2009; 35: 36–45.
- [35] Jaskille AD, Shupp JW, Jordan MH, Jeng JC. Critical review of burn depth assessment techniques: Part I. Historical review. *Journal of burn care & research : official publication of the American Burn Association* 2009; 30: 937–947.
- [36] Jaskille AD, Ramella-Roman JC, Shupp JW, Jordan MH, Jeng JC. Critical review of burn depth assessment techniques: part II. Review of laser doppler technology. *Journal of burn care & research : official publication of the American Burn Association* 2010; 31: 151–157.
- [37] Hop MJ, Stekelenburg CM, Hiddingh J, et al. Cost-Effectiveness of Laser Doppler Imaging in Burn Care in The Netherlands: A Randomized Controlled Trial. *Plastic and reconstructive surgery* 2016; 137: 166e-176e.
- [38] Ponticorvo A, Burmeister DM, Yang B, Choi B, Christy RJ, Durkin AJ. Quantitative assessment of graded burn wounds in a porcine model using spatial frequency domain imaging (SFDI) and laser speckle imaging (LSI). *Biomedical optics express* 2014; 5: 3467–3481.
- [39] Burmeister DM, Ponticorvo A, Yang B, et al. Utility of spatial frequency domain imaging (SFDI) and laser speckle imaging (LSI) to non-invasively diagnose burn depth in a porcine model. *Burns : journal of the International Society for Burn Injuries* 2015; 41: 1242–1252.